Thoracic Onco2026

The European Congress on Thoracic Oncology

12-13 November 2026 | Rotterdam, The Netherlands

Abstract Book



Bioevents
Sharing Biomed Knowledge

Immune-modulating Effects on Tumor-Draining Lymph Nodes of Neoadjuvant Chemoradiotherapy Combined with Dual Immunotherapy in Patients with T3-4N0-2 NSCLC

***Sofie Koomen*[1,2,3], *Ezgi Ulas*[2,3,4], *Anne Vrijmoet*[5], *Ilias Houda*[2,4], *Ibrahim Korkmaz*[1,3,6,7], *Chris Dickhoff*[2,8], *Idris Bahce*[2,3,4], *Suresh Senan*[2,3,9], *Tanja de Gruijl*[2,3,10], *Marieke Fransen*[2,3,4], *Teodora Radonic*[2,3,5], *Febe van Maldegem*[1,2,3], *Famke Schneiders*[2,3,9]**

[1]*Department of Molecular Cell Biology and Immunology, Amsterdam UMC, Netherlands*
[2]*Cancer Biology and Immunology, Cancer Center Amsterdam, Netherlands*
[3]*Immunology, Amsterdam institute for Immunology and Infectious diseases, Netherlands*
[4]*Department of Pulmonary Medicine, Amsterdam UMC, Netherlands*
[5]*Department of Pathology, Amsterdam UMC, Netherlands*
[6]*Burn Center and Department of Plastic and Reconstructive Surgery, Rode Kruis Ziekenhuis, Alliance of Dutch Burn Care, Netherlands*
[7]*Department of Plastic, Reconstructive and Hand Surgery, Amsterdam Movement Sciences (AMS) Institute, Netherlands*
[8]*Department of Cardiothoracic Surgery, Amsterdam UMC, Netherlands*
[9]*Department of Radiation Oncology, Amsterdam UMC, Netherlands*
[10]*Department of Medical Oncology, Amsterdam UMC, Netherlands*

Background: Tumor-draining lymph nodes (TDLNs) play a key role in inducing and promoting antitumor immunity. TDLNs are commonly situated near the primary tumor and are therefore often exposed to therapeutic radiation. The effects of concurrent immunotherapy and radiation on TDLN immune function remain poorly understood. We investigated these effects in patients with T3-4N0-2 non-small cell lung cancer (NSCLC) using immunohistochemistry and spatial transcriptomics.

Methods: This observational cohort study analyzed TDLNs from two groups: (1) patients from the INCREASE trial, treated with neoadjuvant ipilimumab/nivolumab (IPI/NIVO) plus chemoradiotherapy (CRT) (n=25) and (2) patients from a matched control cohort, treated with neoadjuvant CRT alone (n=25). TDLNs were categorized by cumulative radiation dose as low (≤5 Gy), intermediate (20-30 Gy), or high (50-60 Gy). Duplex immunohistochemistry assessed CD8/Ki67, PD-1/FOXP3, and CD8/cleaved caspase-3. GeoMx spatial transcriptomics was performed on a subset of TDLNs to profile CD8/Ki67+ T-cell hotspots.

Results: Compared with CRT alone, addition of IPI/NIVO induced robust type I immune responses and showed increased CD8+ and regulatory T cell levels in irradiated TDLNs, with effects observed across all radiation dose groups and most pronounced in high-dose TDLNs. High radiation exposure was associated with extracellular matrix and macrophage-related gene signatures indicative of fibrosis and prolonged inflammation, which were partially alleviated by immunotherapy.

Conclusion: Neoadjuvant IPI/NIVO plus CRT elicited robust TDLN immune responses despite high-dose radiation exposure. Although radiation-induced fibrosis occurred, immune responses were not diminished compared with low-dose TDLNs, highlighting the resilience of TDLN immune function under intense radiation exposure.

Epigenetic Silencing of OX40 in Lung Squamous Cell Carcinoma: A Potential Target for Immunomodulation

***Konrad Pawelczyk*[1], *Joanna Dragan*[2], *Julia Depta*[2], *Beata Muszczyńska-Bernhard*[3], *Marcel Dudzic*[1], *Monika Jasek*[2], *Marta Wagner*[2]**

[1]*Department of Thoracic Surgery, The Lower Silesian Center for Oncology, Pulmonology and Hematology, Poland*
[2]*Laboratory of Genetics and Epigenetics of Human Diseases, Hirszfeld Institute of Immunology and Experimental Therapy, Polish Academy of Sciences, Poland*
[3]*Department of Pathomorphology II, Lower Silesian Center for Oncology, Pulmonology and Hematology, Poland*

Background: Growing evidence suggests that inadequate T-cell priming is a major barrier to the efficacy of immune checkpoint blockade. Beyond TCR-mediated antigen recognition, effective T-cell activation requires costimulatory signals, which are often impaired in the tumor microenvironment. Attention has increasingly focused on members of the TNF receptor superfamily (TNFRSF), which mediate costimulatory signals and have emerged as promising targets to enhance antitumor T-cell responses.

Objectives: The objective of the study was to evaluate the epigenetic regulation of OX40 expression, one of the TNFRSF members, that may potentially represent a promising addition to the repertoire of immunomodulatory strategies.

Methods: Methylation status, assessed by pyrosequencing, and mRNA expression levels, quantified using ddPCR, were analyzed in 17 surgically resected lung squamous cell carcinoma (LUSC) specimens and 32 samples from patients with lung adenocarcinoma (LUAD).

Results: OX40 mRNA expression was significantly lower in tumor (T) than adjacent non-tumor tissue (NT) exclusively in patients with LUSC ($p = 0.0327$). Similarly, differential OX40 methylation between T and NT was observed only in the LUSC group ($p = 0.0083$). Furthermore, OX40 promoter methylation inversely correlated with mRNA expression ($p = 0.0010$, $r = -0.7387$, 95% CI = (-0.9027,- 0.3869)). No such association was detected in patients with LUAD.

Conclusion: Reduced OX40 expression may contribute to tumor immune evasion by impairing T-cell proliferation, survival, and cytotoxic activity. The observed association between OX40 expression and promoter methylation in LUSC suggests that targeting DNA methylation may represent a potential approach to restore OX40 expression and enhance antitumor immune responses.

Acupuncture for Preventing Chemotherapy-Induced Peripheral Neuropathy (CIPN)

***Hang Liu*[1]**, *George Lenon*[1], *Zhen Zheng*[1], *Frances Barnett*[2]

[1]*School of Health and Biomedical Sciences, RMIT University, Australia*
[2]*Oncology Department, Northern Health, Australia*

Background: Chemotherapy-Induced Peripheral Neuropathy (CIPN) is nerve damage by Chemotherapy, leading to numbness and sharp pain. Around 70% of patients experience CIPN first month after chemotherapy, and 30% still have symptoms at six months, significantly reducing quality of life.

Objectives: This study aims to evaluate the feasibility, preliminary effectiveness, and safety of acupuncture in preventing CIPN in patients with early-stage colorectal cancer through a three-stages.

Methods: Stage 1: Systematic review (SR)of acupuncture for Preventing CIPN in all cancer types.
Stage 2: Design study protocol.
Stage 3: Clinical trials: Primary outcomes: feasibility and preliminary effectiveness of acupuncture for preventing CIPN. Secondary outcomes: safety and experiences of patients and healthcare practitioners.

Results: Stage 1:SR identified evidence suggesting acupuncture may prevent the incidence / severity of CIPN.
Stage 2: The study protocol was completed: a randomised trial with adults (≥18 years) receiving mFOLFOX chemotherapy. 30 participants will be randomised to acupuncture (n = 15; weekly for 24 weeks, follow-up to 28 weeks) or controlled group (n = 15). 15 participants and 6 healthcare practitioners will be interviewed.
Stage 3: The clinical trial was granted ethics approval from the St Vincent's Hospital Melbourne HREC. The clinical trial is registered in Australian New Zealand Clinical Trails Registry (ANZCTR). Registration number is ACTRN12626000671369. The trial is preparing to recruit.

Conclusion: This systematic review provides a synthesis of data on acupuncture for preventing CIPN and informed the design of study trial. The clinical trial will determine whether acupuncture is a feasible, potential and safe non-pharmacological intervention that could be integrated into standard oncology care to prevent CIPN.The clinical trial will provide preliminary effectiveness data of acupuncture for preventing CIPN to design larger trial in future.

MESO-GUARD: Prophylactic Interleukin-12/23p40 Inhibition to Reduce Toxicity from Dual Immune Checkpoint Blockade in Pleural Mesothelioma

***Alwin A. Mink*[1,2]*, Daphne W. Dumoulin*[1,2]*, Maria E. Dammeijer-Joosse*[1,2,3]*, Joachim G.J.V. Aerts*[1,2]**

[1]Department of Pulmonary Medicine, Erasmus University Medical Center, Netherlands
[2]Erasmus MC Cancer Institute, Erasmus University Medical Center, Netherlands
[3]Department of Medical Oncology, Erasmus University Medical Center, Netherlands

Background: Immune checkpoint blockade (ICB) has improved outcomes across solid tumors, but is frequently complicated by immune-related adverse events (irAEs). In pleural mesothelioma (PM), 27.7% of patients receiving dual ICB develop grade ≥3 irAEs (1), often necessitating treatment discontinuation and immunosuppression. We identified elevated circulating IL-12/IL-23p40 levels after a single ICB cycle in patients who subsequently developed irAEs. In murine models, IL-12/IL-23p40 inhibition reduced ICB-induced colitis severity without compromising antitumor efficacy (2). Together, these findings suggest IL-12/IL-23p40 contributes to irAE development and can safely be targeted.

Objectives: To investigate whether preemptive IL-12/IL-23p40 inhibition prevents irAEs without compromising antitumor efficacy.

Methods: MESO-GUARD is an open-label, single-center, single-arm phase II trial. Ustekinumab is administered 5-10 days before nivolumab plus ipilimumab, followed by administrations at weeks 8 and 20. The primary endpoint is grade ≥3 irAE incidence within 24 weeks of ICB initiation. Secondary endpoints include objective response rate, duration of response, progression-free survival, and time to irAE onset. Translational analyses include peripheral immune and proteomic profiling and circulating cell-free DNA dynamics. Forty-two patients will be enrolled.

Results: As of 15 September 2026, 7 patients have been enrolled, of whom 4 received ustekinumab and 3 have initiated ICB. After a median follow-up of 20 days from ICB initiation, no grade ≥3 irAEs have occurred among patients who initiated ICB. No ustekinumab-related adverse events or unexpected safety signals were observed.

Conclusion: Prophylactic IL-12/IL-23p40 inhibition preceding dual ICB appears feasible, with no new safety signals observed to date. Follow-up will determine the effect on irAE incidence and antitumor efficacy.

References: 1 Dumoulin DW, Douma LH, Hofman MM, van der Noort V, Cornelissen R, de Gooijer CJ, et al. Nivolumab and ipilimumab in the real-world setting in patients with mesothelioma. Lung Cancer. 2024 Jan;187:107440.
2 Groeneveldt C, Vadgama D, Onrust-van Schoonhoven A, Whyte D, Hofman MM, Rozendaal NE, van Nimwegen M, Eterman M, Dumoulin DW, Mathijssen RH, Joosse A. Neutralizing the IL-12/IL-23 p40 subunit prevents immune checkpoint blockade toxicity without compromising antitumor efficacy. Cancer Immunology Research. 2026 Aug 31.

Figure 1. Timeline of study-related interventions. IV = intravenous, s.c. = subcutaneous, ipi = ipilimumab, nivo = nivolumab. Blood drop indicates blood drawing. Pen and paper indicate questionnaire. CT indicates CT scan of the thorax and upper abdomen.

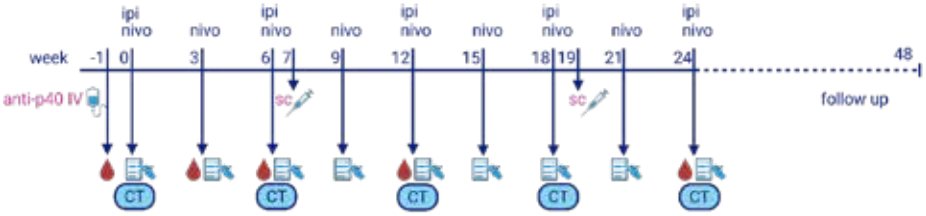

Reducing Overdiagnosis in Clinical Practice: Recognizing Benign Mimics of Adenocarcinoma-Spectrum Lesions on Thoracic CT

Dongming Xu

Radiology, University of Pennsylvania, USA

Accurate characterization of pulmonary nodules is increasingly important with the widespread use of high-resolution CT and lung cancer screening. However, nonsolid and part-solid nodules initially suspected to represent adenocarcinoma-spectrum lesions frequently prove to be benign, creating a risk of overdiagnosis, unnecessary follow-up, invasive procedures, patient anxiety, and overtreatment.

This educational exhibit reviews the CT features of adenocarcinoma-spectrum lesions and highlights common benign mimics that may present as nonsolid or part-solid nodules. Benign causes include infection and inflammation, focal atelectasis, hemorrhage, pulmonary contusion, pulmonary infarction, drug-induced lung injury, and lymphoid interstitial pneumonia (LIP). Although persistent subsolid nodules warrant careful evaluation, many benign lesions resolve, regress, or demonstrate fluctuating appearances on follow-up imaging.

Emphasis is placed on imaging features that improve diagnostic confidence, including lesion morphology, lesion distribution, internal attenuation, and the presence or absence of characteristic findings such as air bronchograms, bubble-like lucencies, and pleural retraction. The value of multiplanar reformations and longitudinal imaging assessment is illustrated, along with integration of relevant clinical information such as symptoms, fever, leukocytosis, recent trauma, medication exposure, and thromboembolic disease.

Particular attention is given to common pitfalls that lead to premature labeling of nonsolid or part-solid nodules as adenocarcinoma-spectrum lesions, especially on baseline examinations in patients without a history of lung adenocarcinoma. The exhibit advocates a descriptive approach using the terms nonsolid nodule and part-solid nodule when appropriate and emphasizes the importance of follow-up assessment before assigning a presumptive malignant diagnosis.

Recognition of benign mimics, structured reporting, and careful longitudinal evaluation can improve diagnostic accuracy while reducing overdiagnosis and unnecessary interventions.

Detection of Actionable Mutations Via Next-Generation Sequencing Liquid Biopsy for Targeted Therapy in Advanced Lung Cancer

Vladimir Risteski[1], *Aneta Tanevska Zrmanovska*[1], *Blagica Krsteska*[1], *Selim Komina*[1], *Marija Nikolovska*[1], *Aleksandar Eftimov*[1], *Natasha Tolevska Dimitrovska*[2], *Igor Stojkovski*[3], *Rubens Jovanovic*[1], *Magdalena Bogdanovska Todorovska*[1], *Slavica Kostadinova Kunovska*[1]

[1]*Institute of Pathology, Ss. Cyril and Methodius University, North Macedonia*
[2]*University Clinic for Thoracic and Vascular Surgery, Ss. Cyril and Methodius University, North Macedonia*
[3]*University Clinic for Radiotherapy and Oncology, Ss. Cyril and Methodius University, North Macedonia*

Background: Liquid biopsy is a crucial tool for molecular profiling in advanced non-small cell lung cancer (NSCLC), particularly for guiding novel therapeutic strategies in oncogene-addicted tumors when tissue is limited.

Objectives: To evaluate the diagnostic yield of next-generation sequencing (NGS)-based liquid biopsy in detecting targetable gene alterations to guide treatment paradigms in advanced lung cancer.

Methods: Cell-free DNA (cfDNA) isolated from plasma samples of 52 patients with advanced non-small cell lung cancer (NSCLC) was evaluated using both targeted real-time PCR (rt-PCR) and targeted next-generation sequencing (NGS) via the Oncomine Precision Assay. Comparative analysis focused on variant identification, variant allele frequency (VAF) quantification, and determination of therapeutic actionability.

Results: Clinically significant mutational profiles were positive in 7 of 52 patients (13.5%). NGS successfully detected actionable oncogenic drivers even at remarkably low variant frequencies (<0.1% to 2.5%). Key findings included classic EGFR sensitizing mutations (Exon 19 deletion [AF 1.97%], L858R [VF 0.93%]) mapping directly to targeted TKI therapies. Notably, in one case where targeted real-time PCR for EGFR testing yielded negative results, NGS cfDNA successfully identified pathogenic KRAS mutations (G12D, G13D) alongside other variants. The assay also captured a complex genomic landscape across these 7 patients, detecting concurrent pathogenic alterations and variants of uncertain significance (VUS) in TP53, AKT1, CHEK2, IDH2, and NTRK1.

Conclusion: NGS-based liquid biopsy provides robust diagnostic utility for oncogene-addicted lung cancer. By effectively detecting critical actionable mutations at low allele frequencies, this minimally invasive approach overcomes standard testing limitations and directly informs personalized treatment options.

Spontaneous Chylothorax as an Initial Presentation of Small Cell Lung Cancer: A Case Report

***Joud Khalaf*[1], *Sima Amasheh*[1], *Hana Khalili*[1], *Hanood Abu Rass*[1,2], *Ramzi Shawahna*[1,3]**

[1]*Department of Medicine, Faculty of Medicine and Allied Health Sciences, An Najah National University, Palestinian Authority*
[2]*Department of Physiology, Pharmacology, and Toxicology, Faculty of Medicine and Allied Health Sciences, An Najah National University, Palestinian Authority*
[3]*Clinical Research Center, An-Najah National University Hospital, Palestinian Authority*

Background: This report presents a rare case of recurrent spontaneous chylothorax leading to the diagnosis of small cell lung carcinoma (SCLC). Spontaneous chylothorax is the collection of chyle in the pleural space for a multitude of reasons, ranging from damage to lymphatic vessels to certain types of cancer, particularly Lymphoma. Lung cancer remains the leading cause of cancer-related mortality globally. SCLC is notably aggressive and typically presents with respiratory symptoms, while chylothorax as its initial manifestation is uncommon. This case describes recurrent spontaneous chylothorax leading to the diagnosis of SCLC, with imaging demonstrating superior vena cava (SVC) compression by the underlying mass.

Patient presentation: A 61-year-old male presented with worsening dyspnea, tachypnea, and a productive cough. A chest X-ray (CXR) revealed a right middle zone opacity and a left-sided pleural effusion. Diagnostic thoracentesis was performed, yielding milky-white fluid. Biochemical analysis confirmed a chylothorax with elevated triglyceride levels. A CT scan of the chest revealed a suspicious large mass occluding the superior vena cava (SVC) and right upper pulmonary artery, as well as mediastinal lymphadenopathy. Subsequent biopsy confirmed the diagnosis of SCLC. The patient began palliative chemotherapy, and his dyspnea significantly improved.

Conclusion: This case highlights an uncommon presentation of SCLC with recurrent spontaneous chylothorax and demonstrates an associated mechanism of SVC compression. It emphasises the importance of investigating spontaneous or recurrent chylothorax for an underlying malignancy and illustrates the role of cross-sectional imaging in identifying the underlying cause. Chylothorax should be considered a potential, although rare, presenting feature of SCLC.

Local B Cell Infiltration as Predictive Biomarker in Stage IV NSCLC

***Michiel Huigen*[1,2]*, Frank Borm*[3]*, Pieter Van der Velden*[4,6]*, Egbert Smit*[5,6]

[1]*Department of Pathology, Leiden University Medical Center, Netherlands*
[2]*Department of Immunology, Leiden University Medical Center, Netherlands*
[3]*Department of Thoracic Oncology, NKI-AvL, Netherlands*
[4]*Department of Ophthalmology, Leiden University Medical Center, Netherlands*
[5]*Department of Pulmonary Diseases, Leiden University Medical Center, Netherlands*
[6]*Contributed equally*

Background: Despite PD-L1 status as biomarker in stage IV Non-Small Cell Lung Cancer (NSCLC), treatment outcomes after pembrolizumab remain difficult to predict. Spatial genomics identified B-cells as hypothesized predictive biomarker.

Objectives: We aimed to develop a DNA-based assay to quantify B-cells and to validate whether B-cell infiltration predicts progression-free survival (PFS) and overall survival (OS) in stage IV NSCLC.

Methods: 174 patients with stage IV NSCLC and pembrolizumab treatment were included. Residual material from their non-lymph-node, diagnostic biopsy was classified as B-cell-rich (>5% B cells) or B-cell-poor. Multivariate cox regression and Kaplan-Meier analysis evaluated associations between a positive B-cell test and PFS or OS.

Results: A positive B-cell test was associated with an HR of 0.57 (p=0.012) for OS and 0.59 (p=0.007) for PFS. Patients with both adequate B-cell infiltration and PD-L1 positivity had a median PFS of 33 months (HR=0.22, p<0.001) and a median OS of 46 months (HR=0.21, p<0.001). In comparison, double-negative patients experienced a median PFS of 4.8 months and a median OS of 7.8 months. Within PD-L1 positive patients, 2-year OS was 81% in double-positive patients, compared to 49% when only PD-L1 positive (HR=0.46, p=0.015, Figure 1).

Conclusion: We developed a sustainable method to quantify B-cells in NSCLC samples. Combined assessment of B-cell infiltration and PD-L1 status stratified patients into groups with markedly different long-term outcomes after pembrolizumab treatment.

If confirmed in the planned future validation studies, this biomarker strategy may improve treatment decision-making in metastatic NSCLC.

